

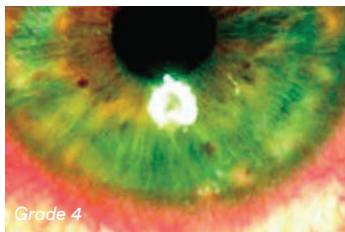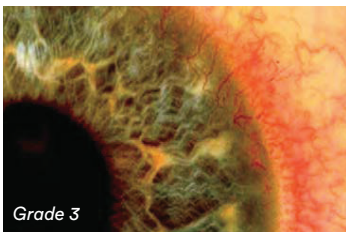
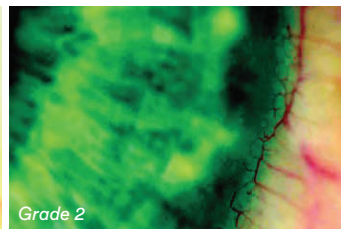
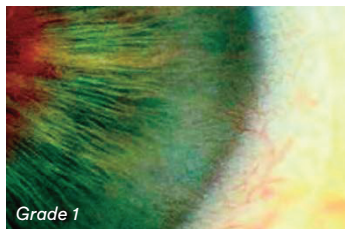
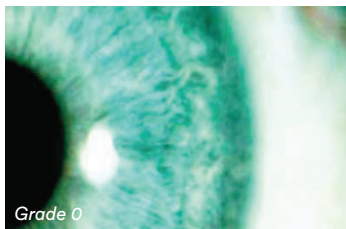
Educational Moments®

How to manage patients with Limbal Redness (Limbal Hyperaemia)

WHAT YOU NEED TO KNOW

Slit Lamp Viewing: • Diffuse beam • Direct illumination • Medium magnification (16x)

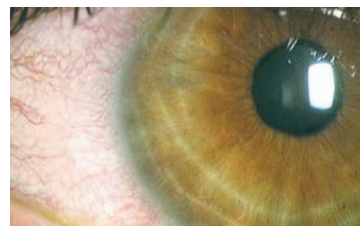
Grading:



- Position: superior, nasal inferior, temporal
- Grade 0: None
- Grade 1: Slight injection of limbal vessels
- Grade 2: Mild injection
- Grade 3: Moderate injection
- Grade 4: Severe injection

Incidence:

- True incidence unknown although common in most lens types. Occurs to some degree with all hydrogel lenses, although may be mild with thin, mid-water hydrogels.



Aetiology:

- Short-term clinical sign of corneal hypoxia – related to oxygen performance of lens
- Inflammation (tight lens syndrome)
- Mechanical irritation (trauma, poor lens fit)
- Atopic/allergic reaction
- Solution sensitivity
- Infection

Symptoms:

- Often none; depends on cause
- Possible pain

Signs:

- Engorged limbal blood vessels with possible subsequent neovascularisation
- May be localised or full coverage, depending on lens type or aetiology, with conjunctival vessel involvement

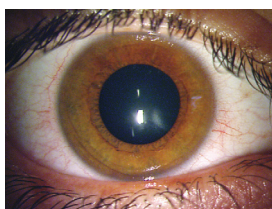


Figure 1: Low magnification, diffuse illumination view of limbal hyperemia

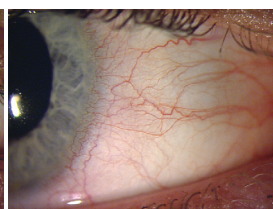


Figure 2: Example of limbal hyperemia

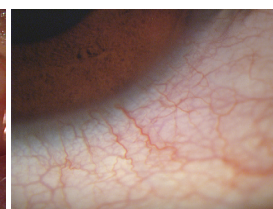


Figure 3: Higher magnification view of limbal hyperemia

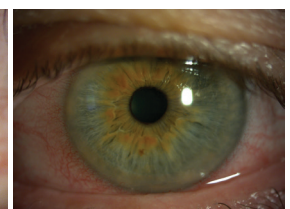

Figure 4: Differential diagnosis: limbal and conjunctival hyperemia secondary to corneal foreign body

Educational Moments[®]

How to manage patients with Limbal Redness (Limbal Hyperaemia)

WHAT YOU NEED TO RECOMMEND TO YOUR PATIENTS

Management:

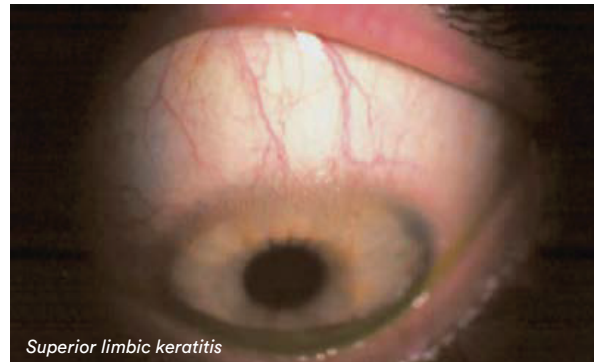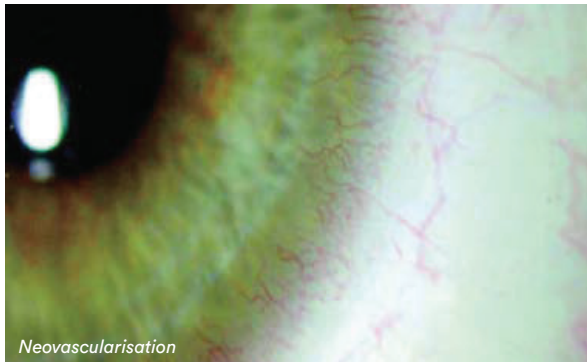
- Manage if \geq grade 2 or if \geq 1 grading scale interval increase or if symptoms occur
- Cease lens wear until resolution. Refit with higher oxygen performance lens materials (Silicone Hydrogel (SiHy), higher Dk/t hydrogel, rigid corneal lenses (RCL))
- Reduce wearing time or change to Daily Disposable (DD)
- Optimise lens fit
- Remove allergen
- Change care system

Prognosis:

- Good – depends on cause
- Reversible
- Noticeable “white-eye” difference between SiHy and traditional hydrogels

Differential Diagnosis:

- Neovascularisation, superior limbic keratoconjunctivitis (SLK), keratitis, CLARE or tight lens syndrome, uveitis, acute glaucoma, intra-ocular infection



FURTHER READING

- du Toit R, et al. Recovery from hyperemia after overnight wear of low and high transmissibility hydrogel lenses. *Curr Eye Res* 2001; 22: 68-73
- Papas E et al. High oxygen-transmissibility soft contact lenses do not induce limbal hyperemia. *Curr Eye Res* 1997; 16 (9): 942-948
- Papas E. On the relationship between soft contact lens oxygen transmissibility and induced limbal hyperaemia. *Exp Eye Res* 1998; 67: 125-31
- Papas E. The role of hypoxia in the limbal vascular response to soft contact lens wear. *Eye Contact Lens* 2003; 29: S72-4; discussion S83-4, S192-4
- Pritchard N et al. Ocular and subjective responses to frequent replacement of daily wear soft contact lenses. *CLAO J* 1996; 22(1): 53-59
- Pult H et al. Limbal and bulbar hyperaemia in normal eyes. *Ophthalmic Physiol Opt* 2008; 28: 13-20
- Szczotka-Flynn LB et al Contact Lenses Manufactured in Etafilcon A Are Noninferior to Two Silicone Hydrogel Lens Types With Respect to Hypoxic Stress. *Eye & Contact Lens* 2018;44:190-9